



## CASO CLINICO 2

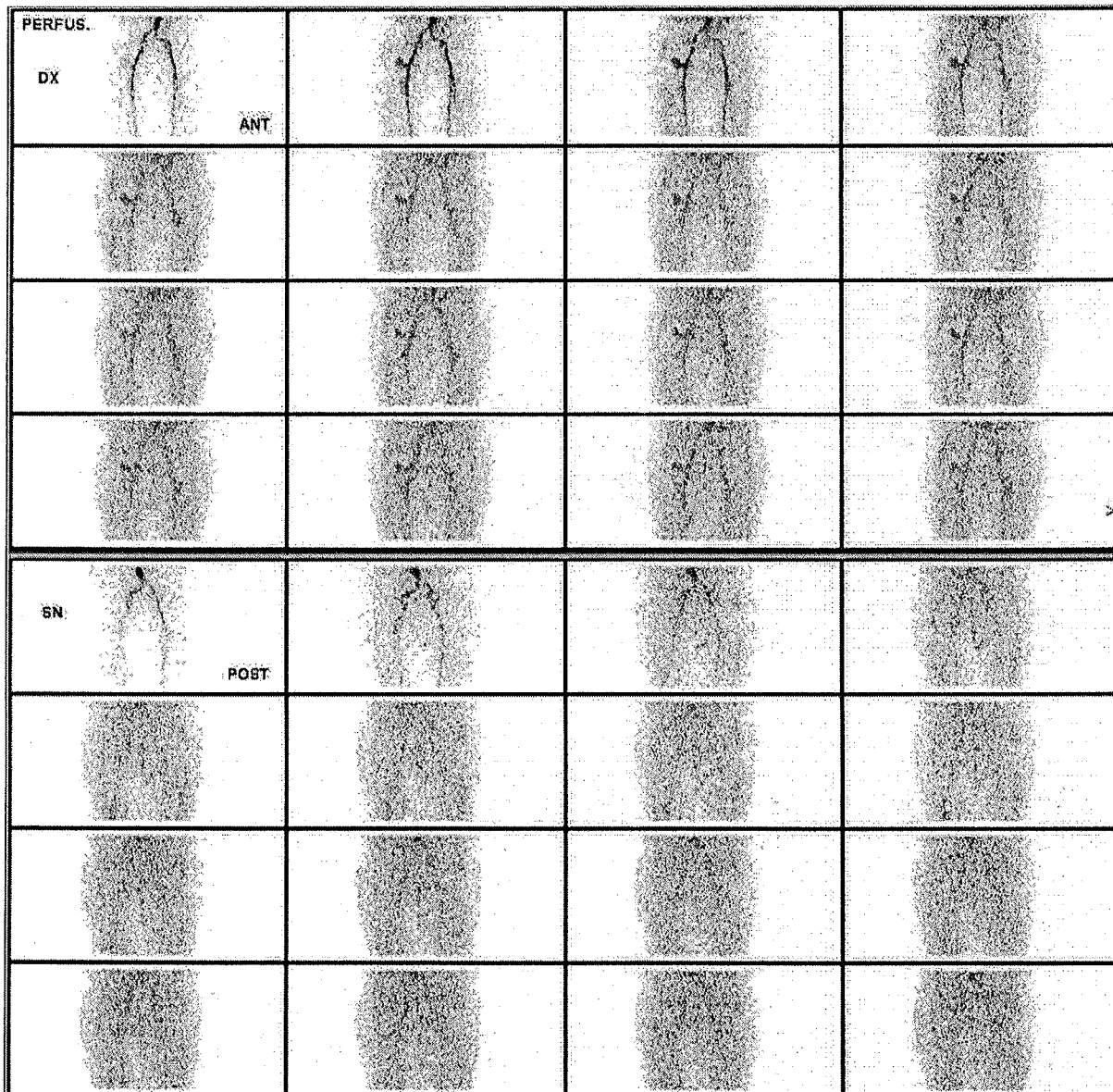
**Quesito diagnostico:** Valutazione in paziente con protesi di anca sinistra (impianto eseguito 11 anni fa) e comparsa di dolore al gluteo sinistro irradiato anteriormente. Mobilizzazione della protesi? Scintigrafia trifasica di approfondimento.


**M, 77 anni**

**In anamnesi:** vasculopatia cerebrale (2 pregressi episodi ictali), coxartrosi, IRC, ipertensione arteriosa, sindrome depressiva, impianto di ATA sx 11 anni fa.

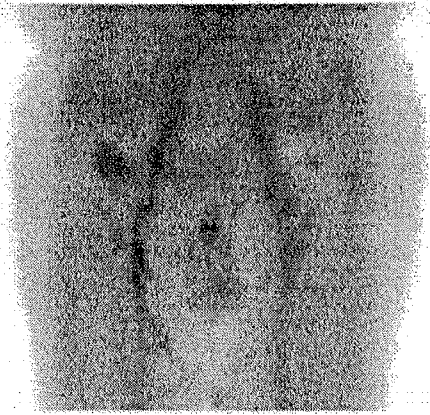
**Rx femore e anca sinistra:** presenza di protesi che appare in sede.

**Si richiede di refertare il caso.**



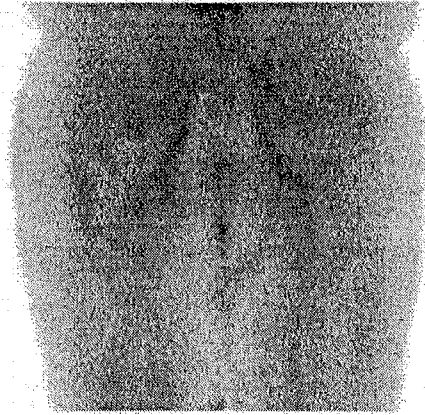


20 avg  
133 max  
1294K



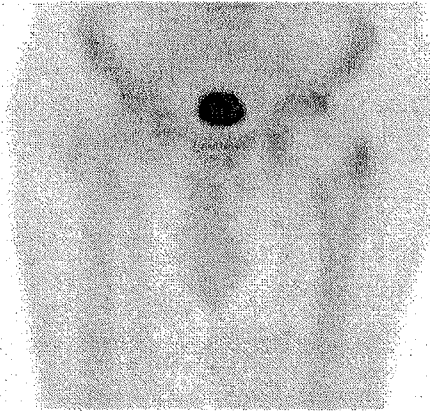
anteriore

16 avg  
102 max  
1077K



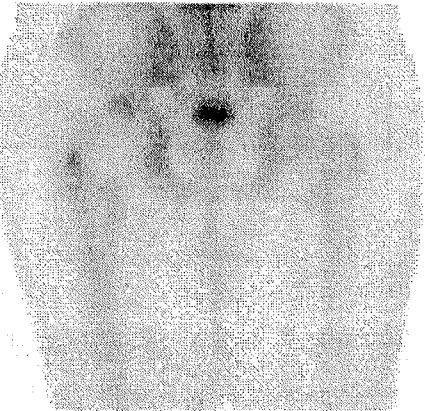
posteriore

27 avg  
553 max  
1799K

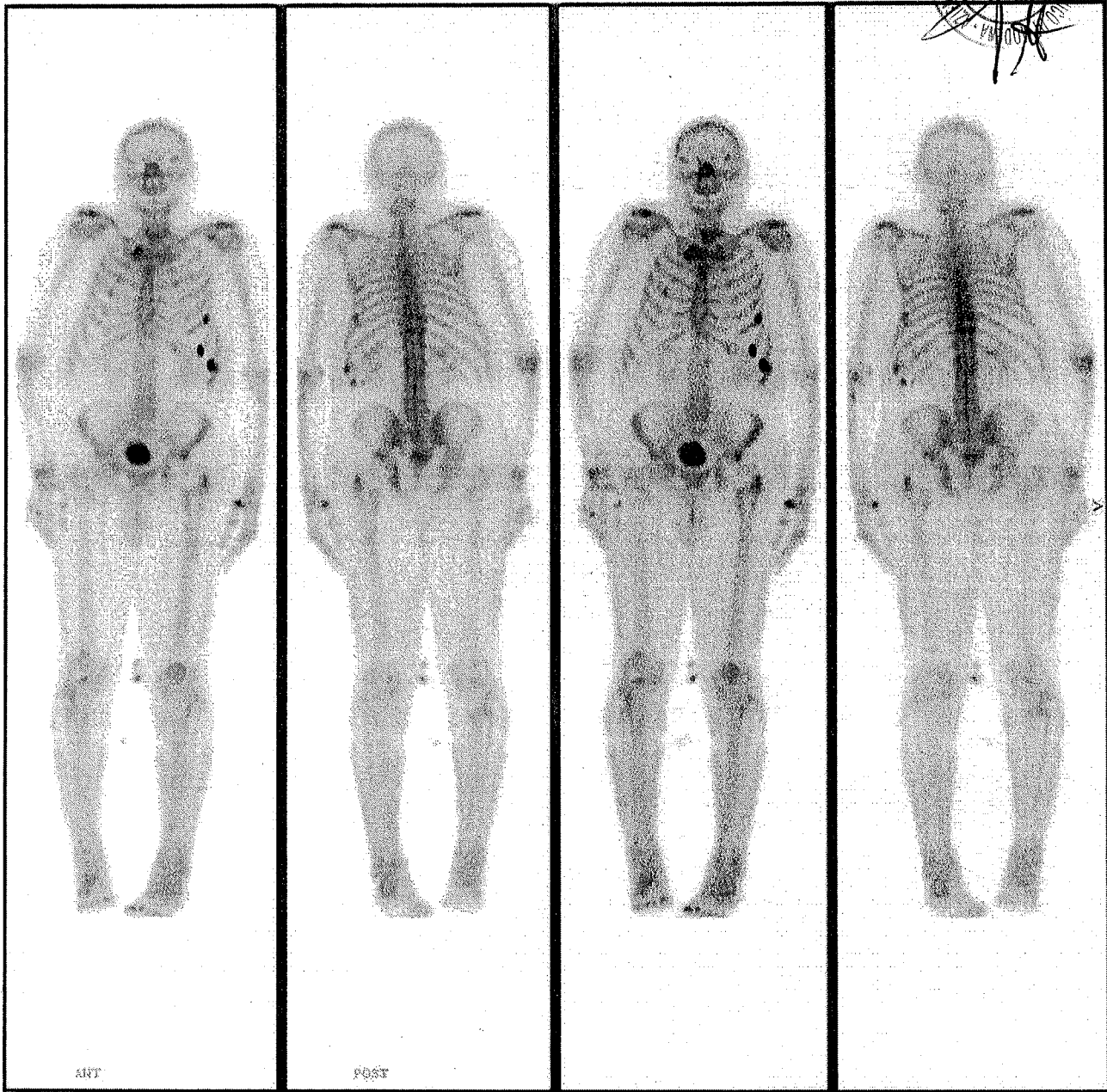



anteriore

26 avg  
553 max  
1729K



posteriore



ANT

POST