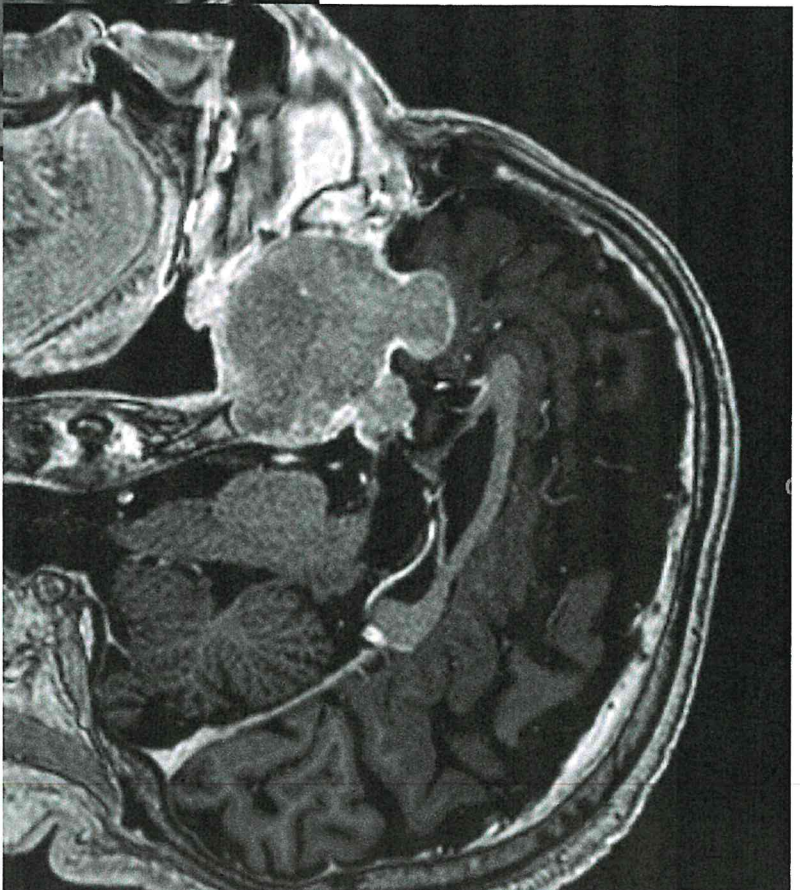
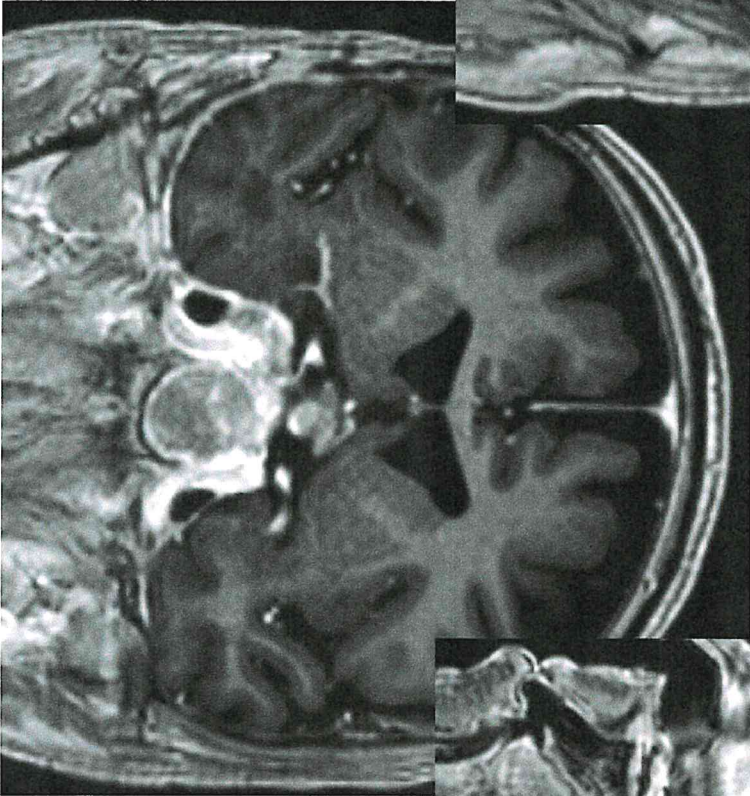
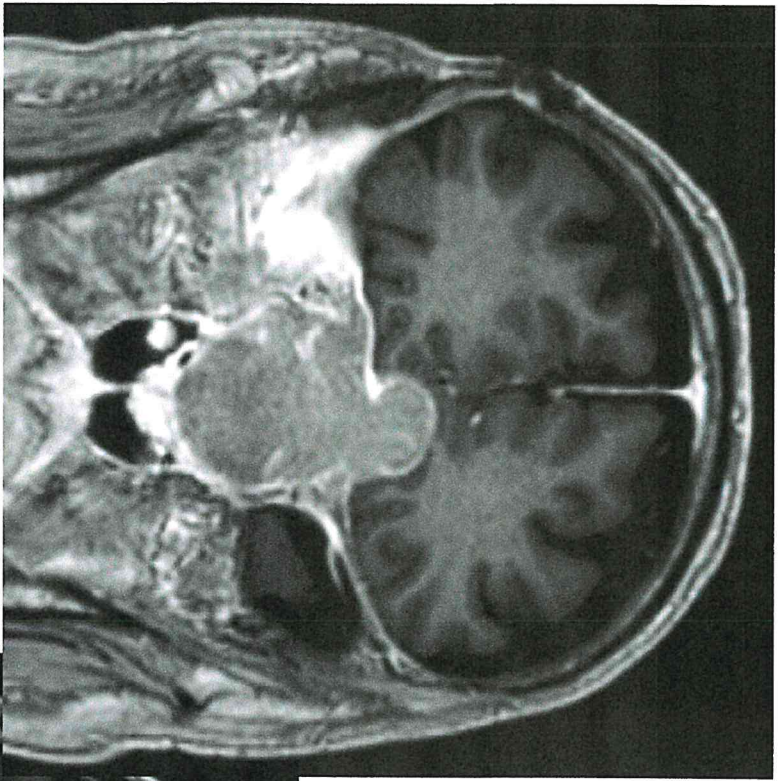
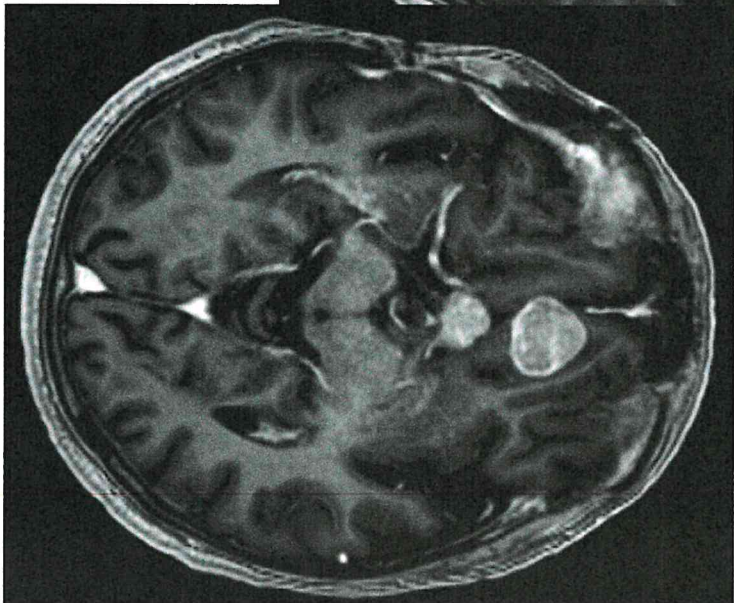
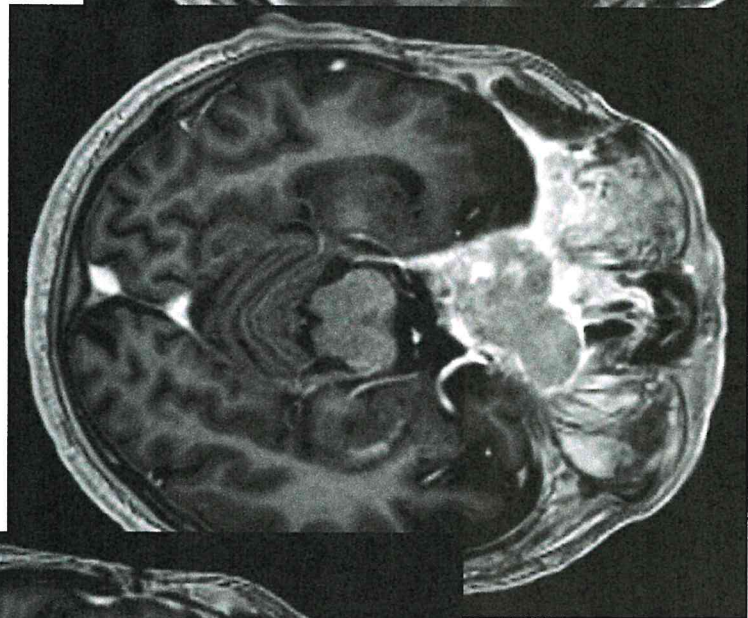
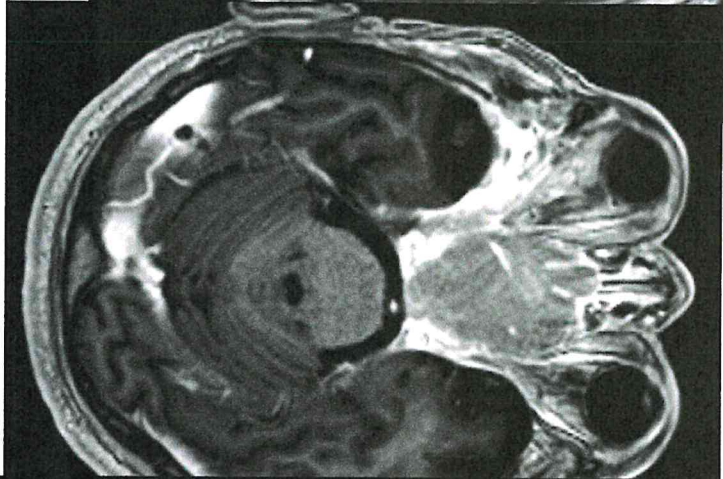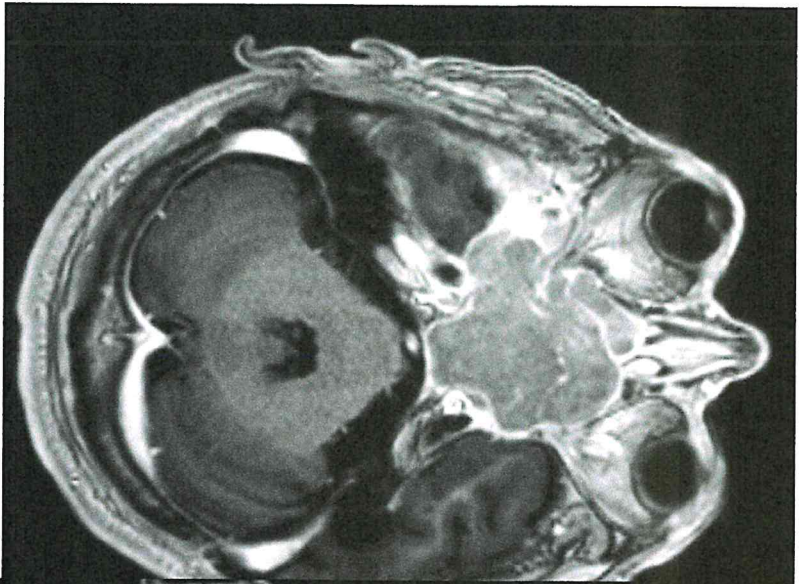


# Maschio, 74aa

*Vigile, collaborante, orientato T/S, eloquio nella norma, grave ipovisus bilaterale peggiore a sinistra, esoftalmo occhio destro, nella norma la motilità ai quattro arti*

---





## PROVA PRATICA NUMERO 1

---

1. Meningioma frontobasale