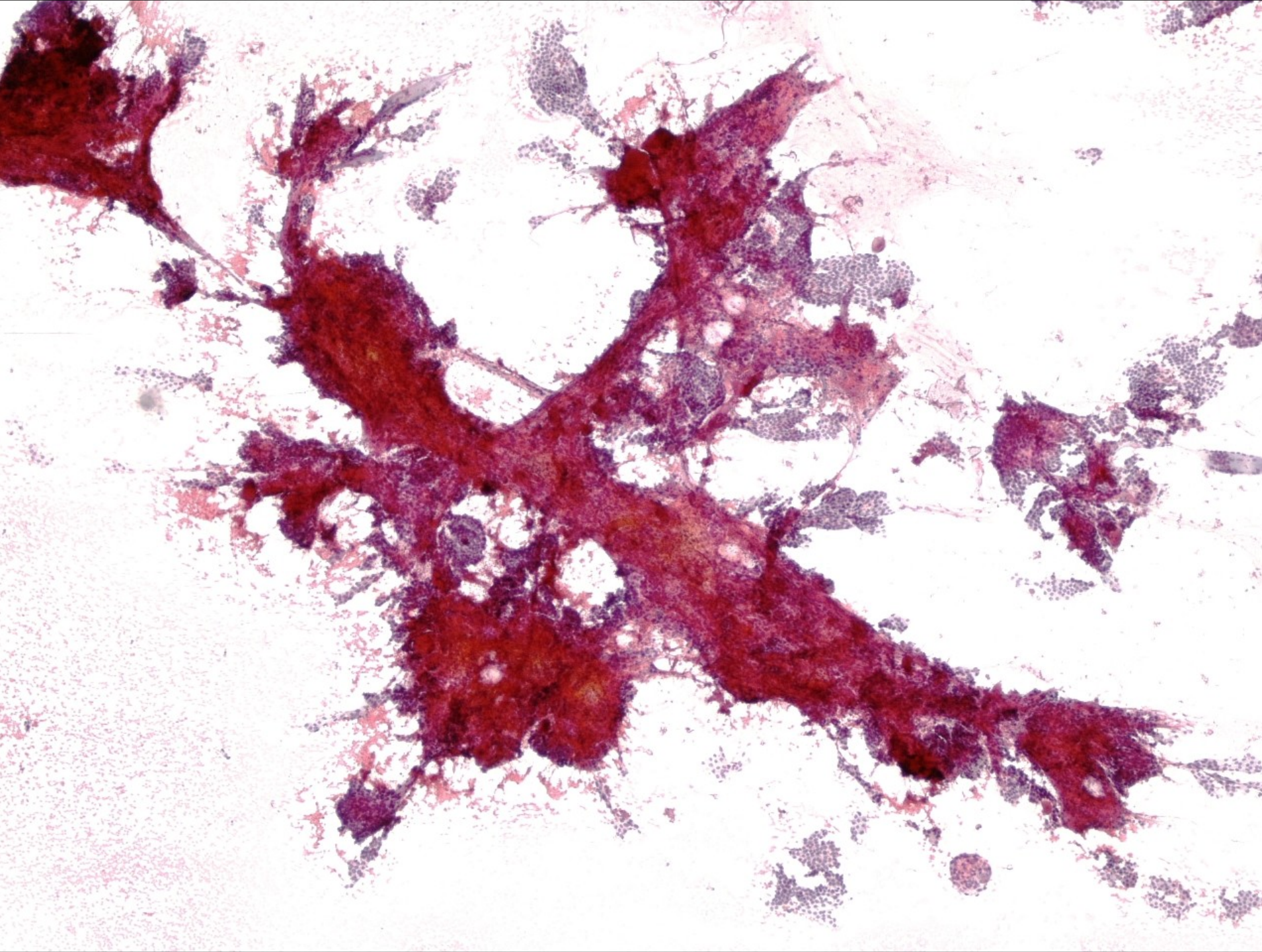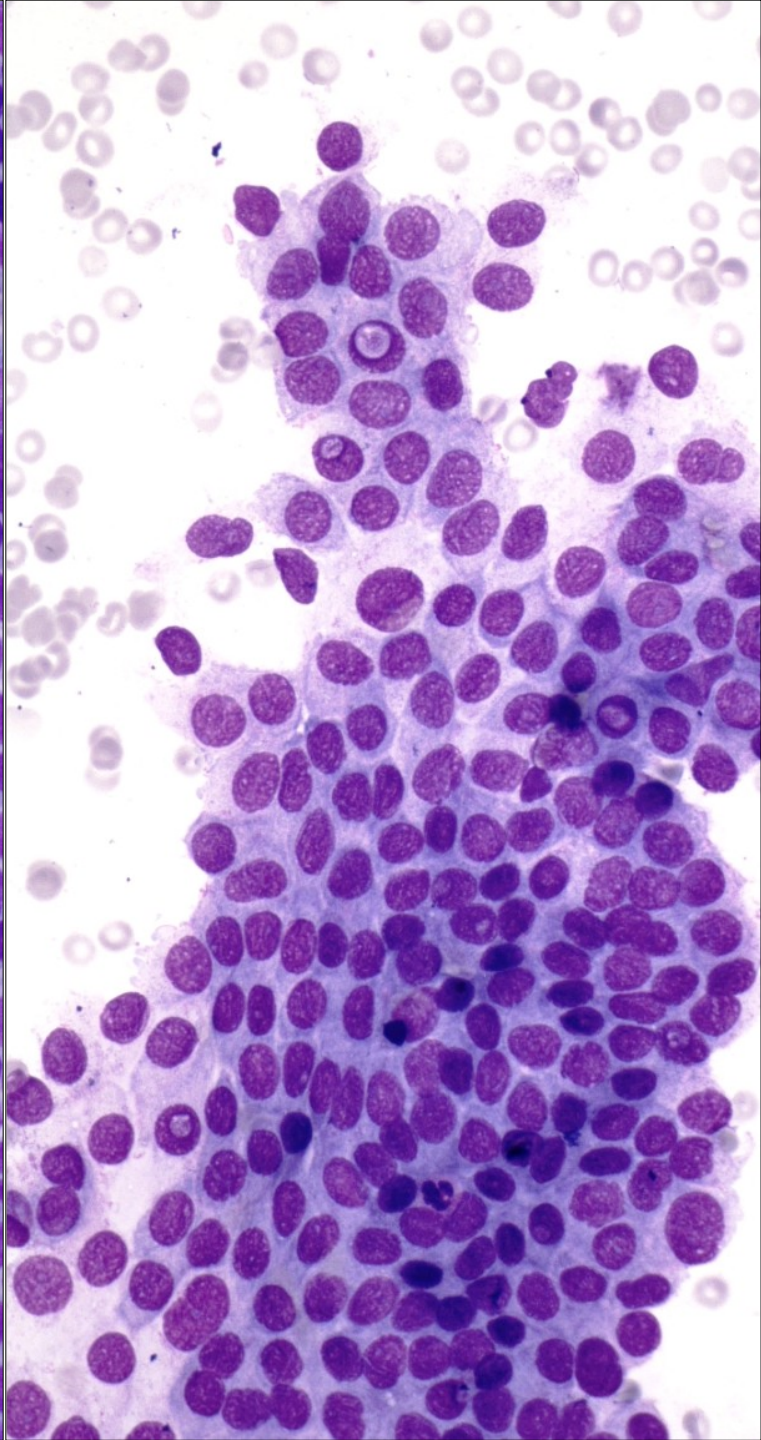
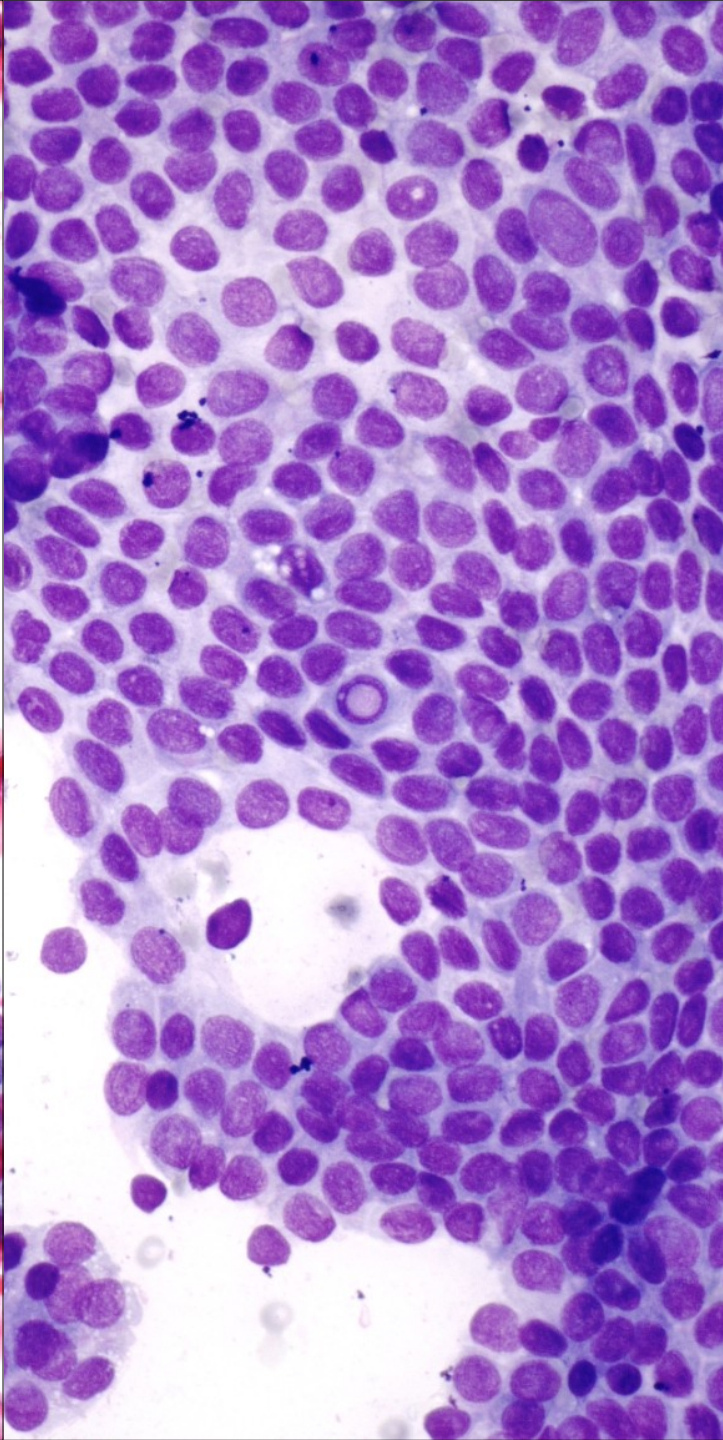
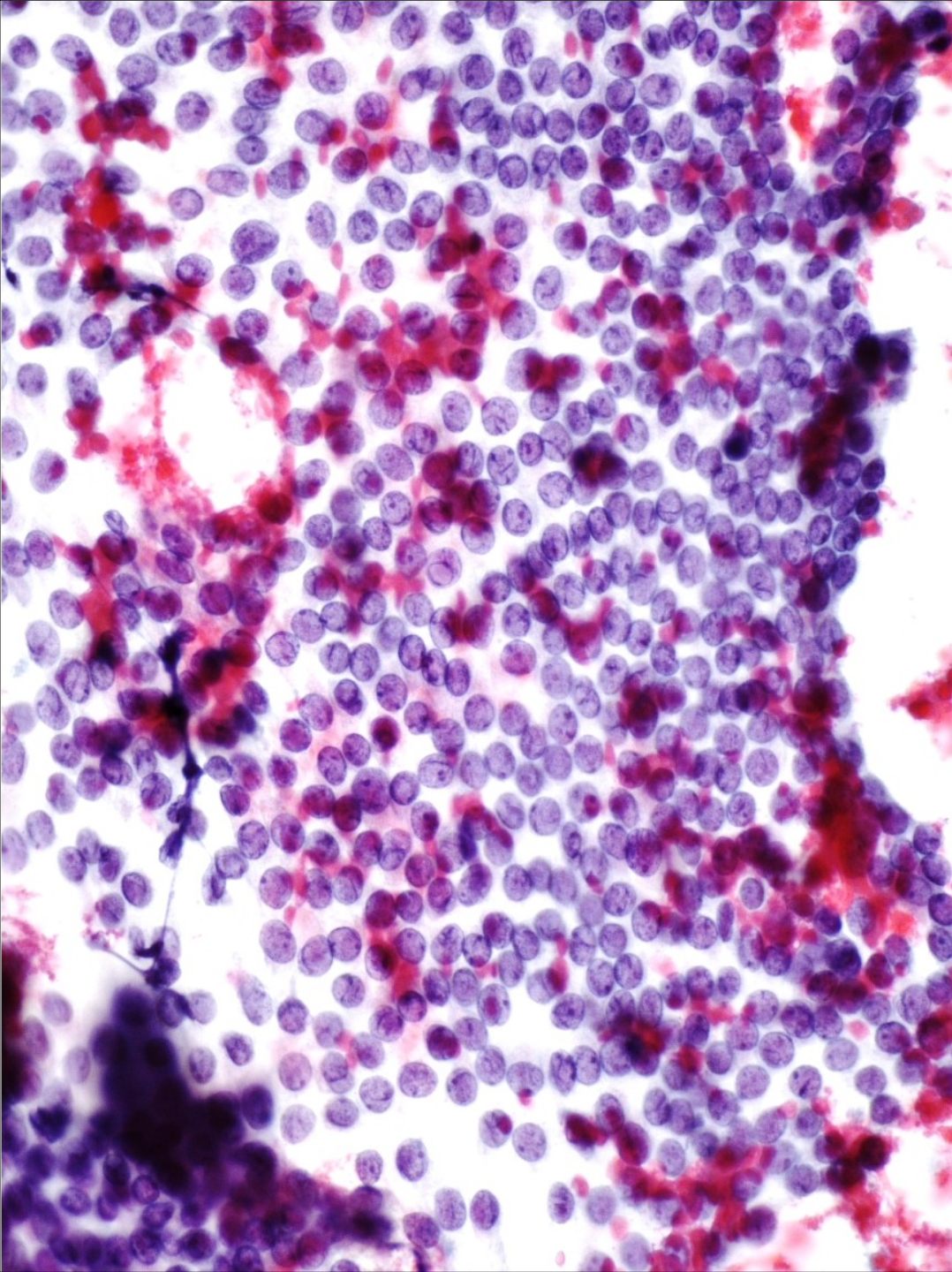
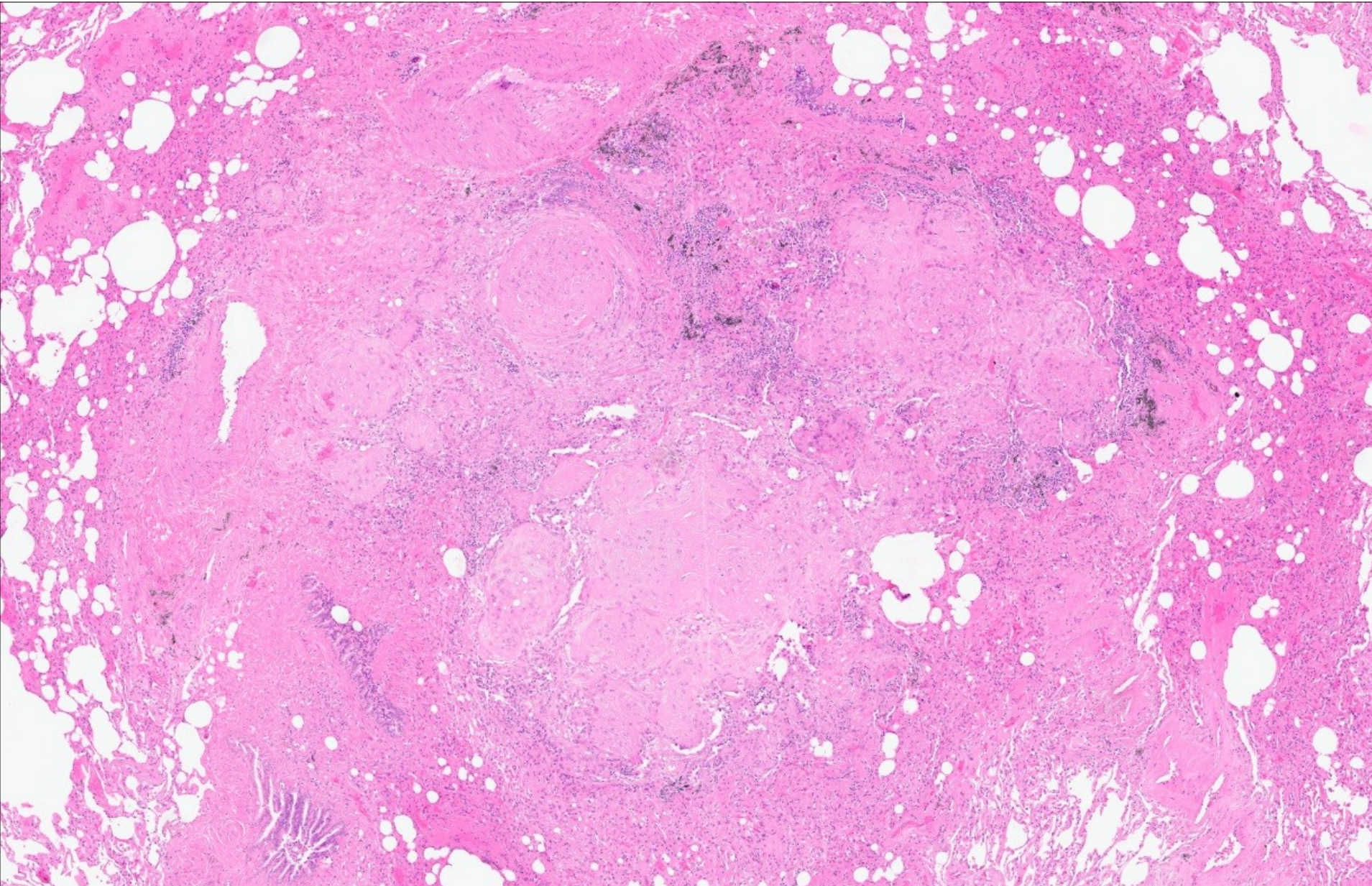


## Caso 1

Agoaspirato  
di nodulo  
tiroideo in  
donna di 35  
anni





## Caso 2

Noduli  
polmonari  
multipli a  
lenta  
evoluzione  
radiologica in  
donna di 50  
anni

